

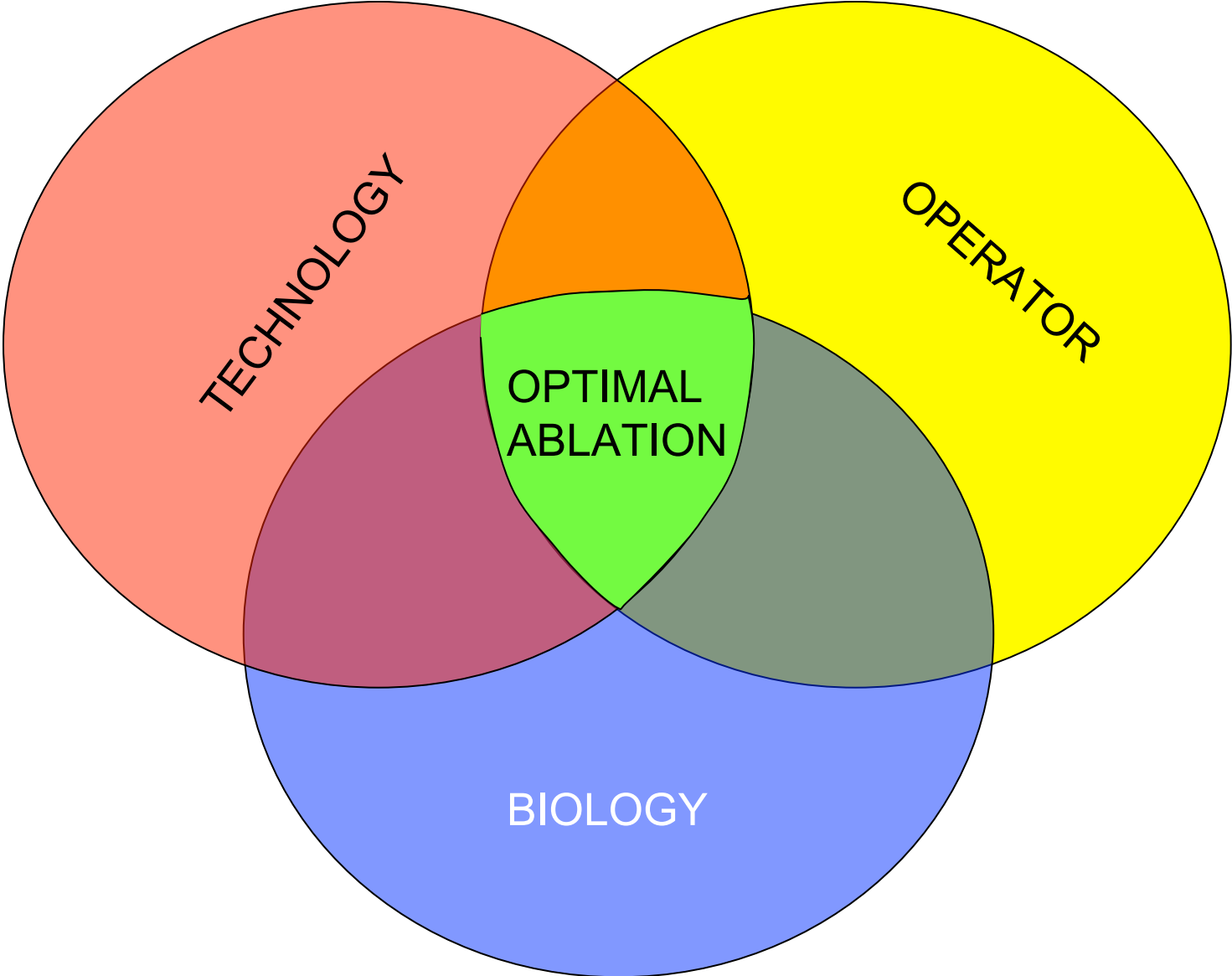
# Nonsurgical Treatment of Thyroid Nodules

## **Laser, Radiofrequency Ablation, MWA, HIFU**

Claudio M Pacella & Enrico Papini

AME-AACE  
November 10, 2018  
Roma

# optimizing tumor ablation


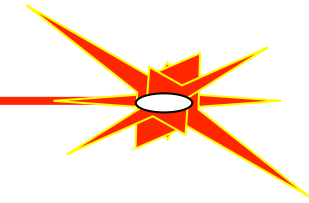


# Hypertermic Ablation

- Thermal ablative therapies, such as radiofrequency, laser and microwave use the energy tissue interaction generated around an inserted applicator.
- Laser energy, like RF and microwave energy, induces electromagnetic heating to raise the temperature of tissues to lethal levels.
- To adequately heat the target cells to induce irreversible injury  
....

(50-54°C for 4-6 minutes is a commonly used endpoint)

# physics & technology



**L**    *Light*  
**A**    *Amplification by*  
**S**    *Stimulated*  
**E**    *Emission of*  
**R**    *Radiation*



## Normal Light

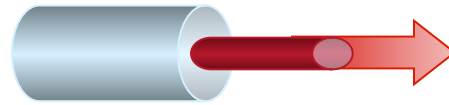
(spontaneous emission)



Low Directionality  
Low Monochromaticity  
Low Coherence  
Low Power

## Laser Light



(stimulated emission)



HIGH Directionality  
HIGH Monochromaticity  
HIGH Coherence  
HIGH Power

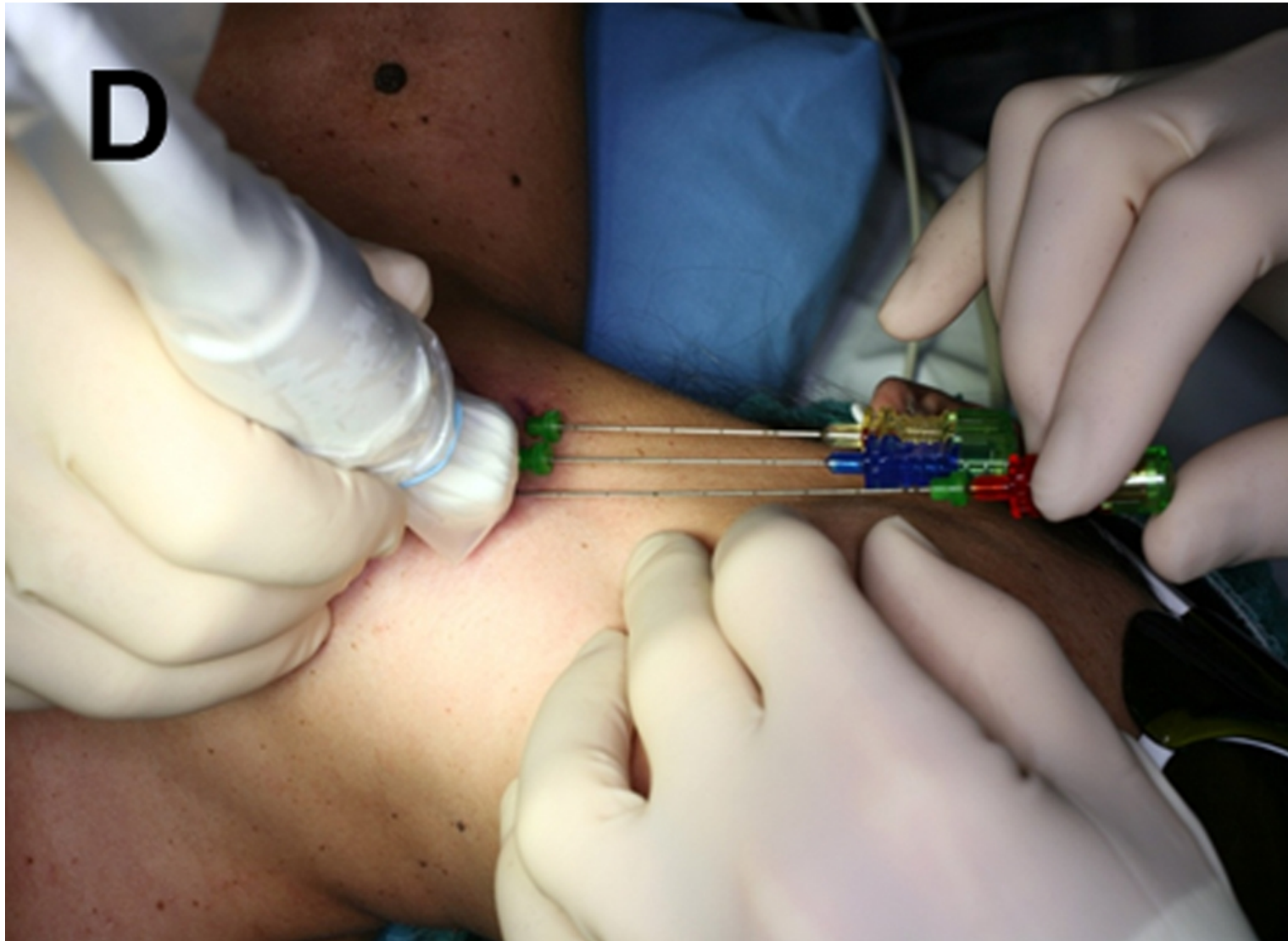
laser technology would afford the delivery of high level energy into a well delimited area of tissue in a predictable, precise and controlled way

# Pacella's technique: flat tip technique

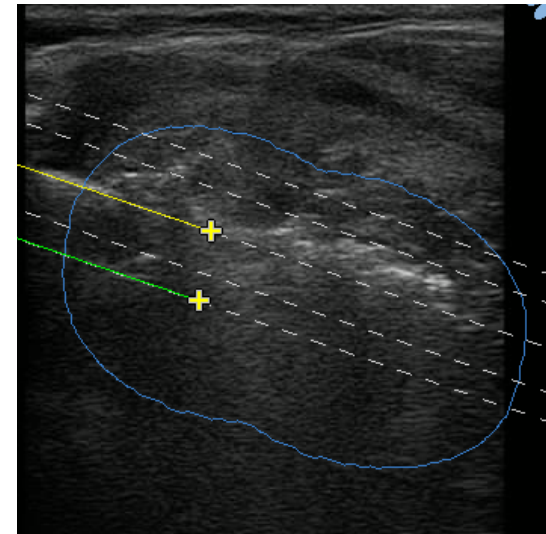
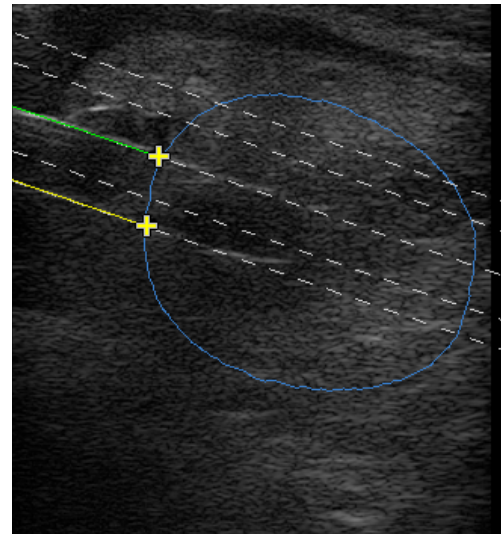
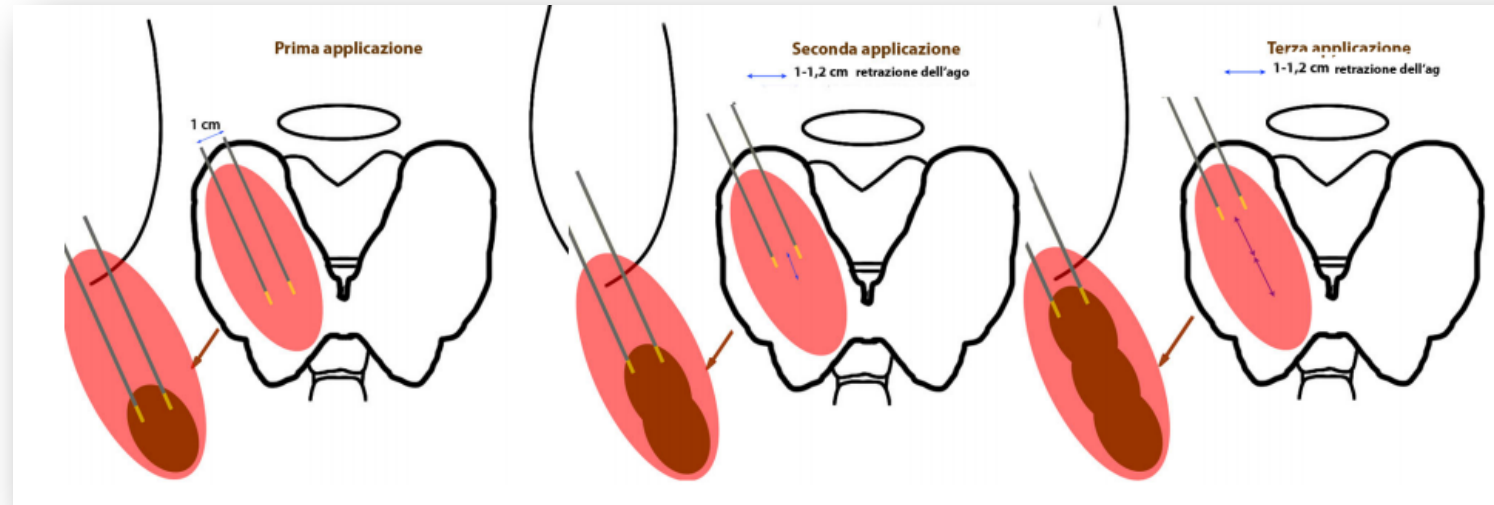


21 Chiba needle

300  $\mu\text{m}$  quartz fiberoptic



**placement of Chiba G21 needles along cranio-caudal major nodule axis;  
needles are separated by 10 mm.**



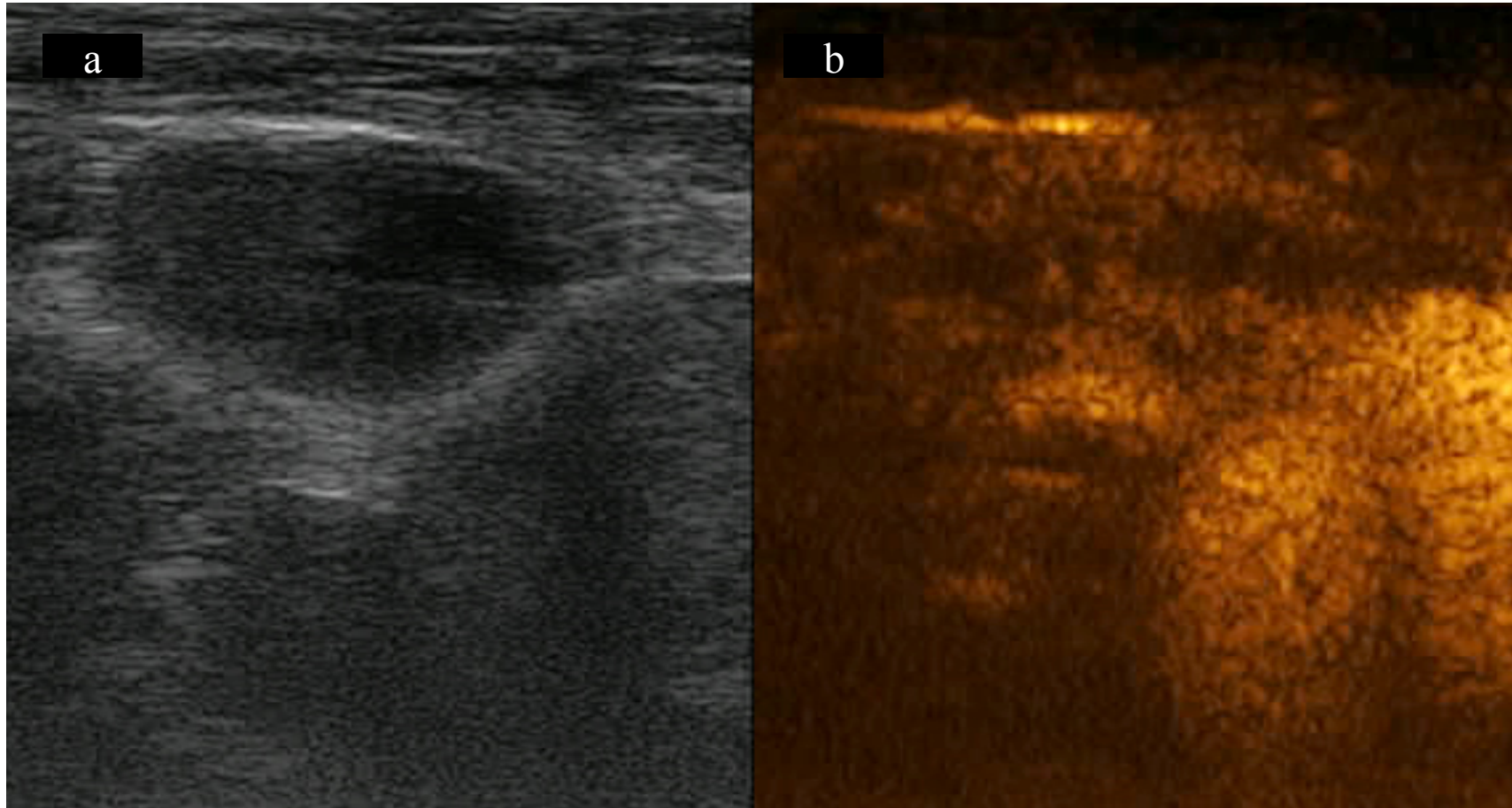


# LA in metastatic lymph nodes from MPCT

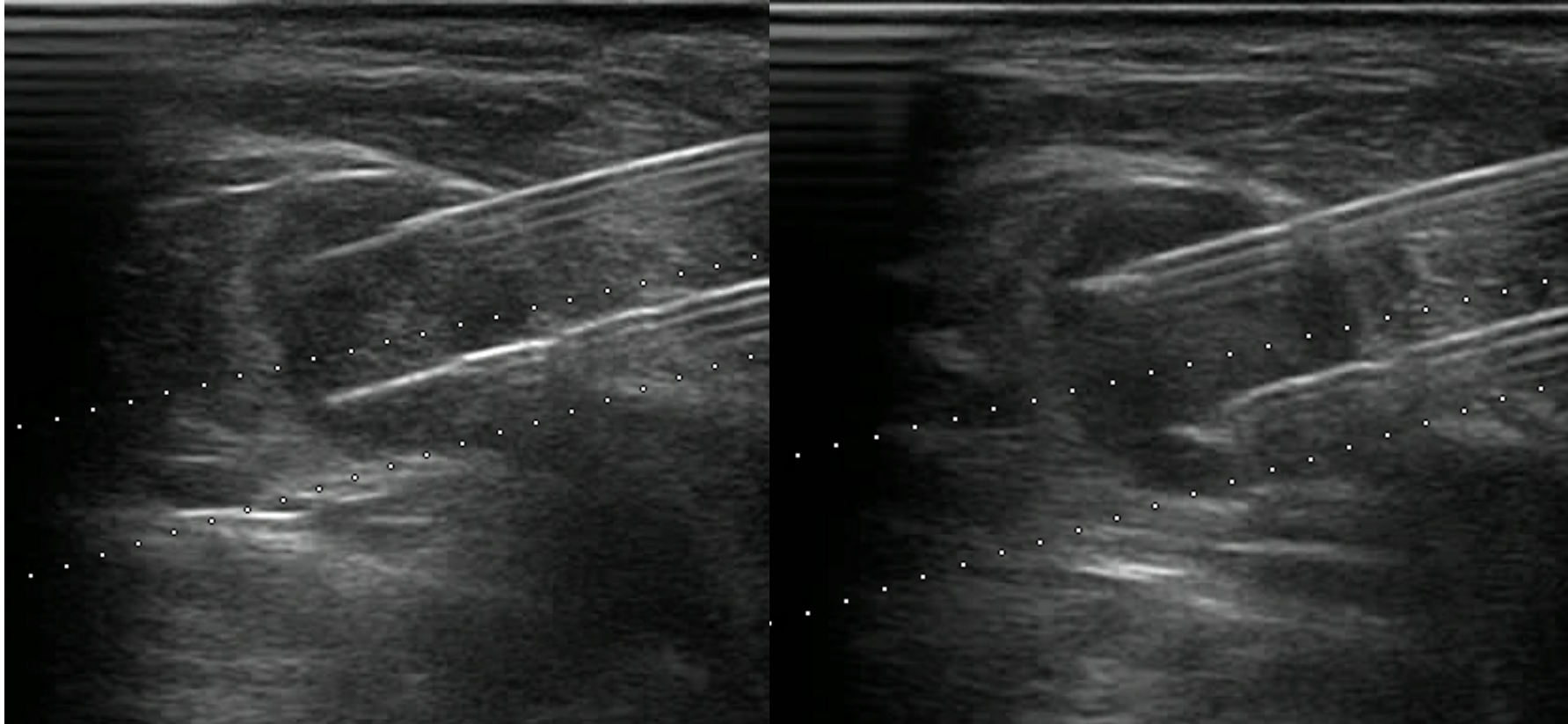
[Percutaneous ultrasound-guided laser ablation is effective for treating selected nodal metastases in papillary thyroid cancer.](#)

Papini E, Bizzarri G, Bianchini A, Valle D, Misischi I, Guglielmi R, Salvatori M, Solbiati L, Crescenzi A, Pacella CM, Gharib H.

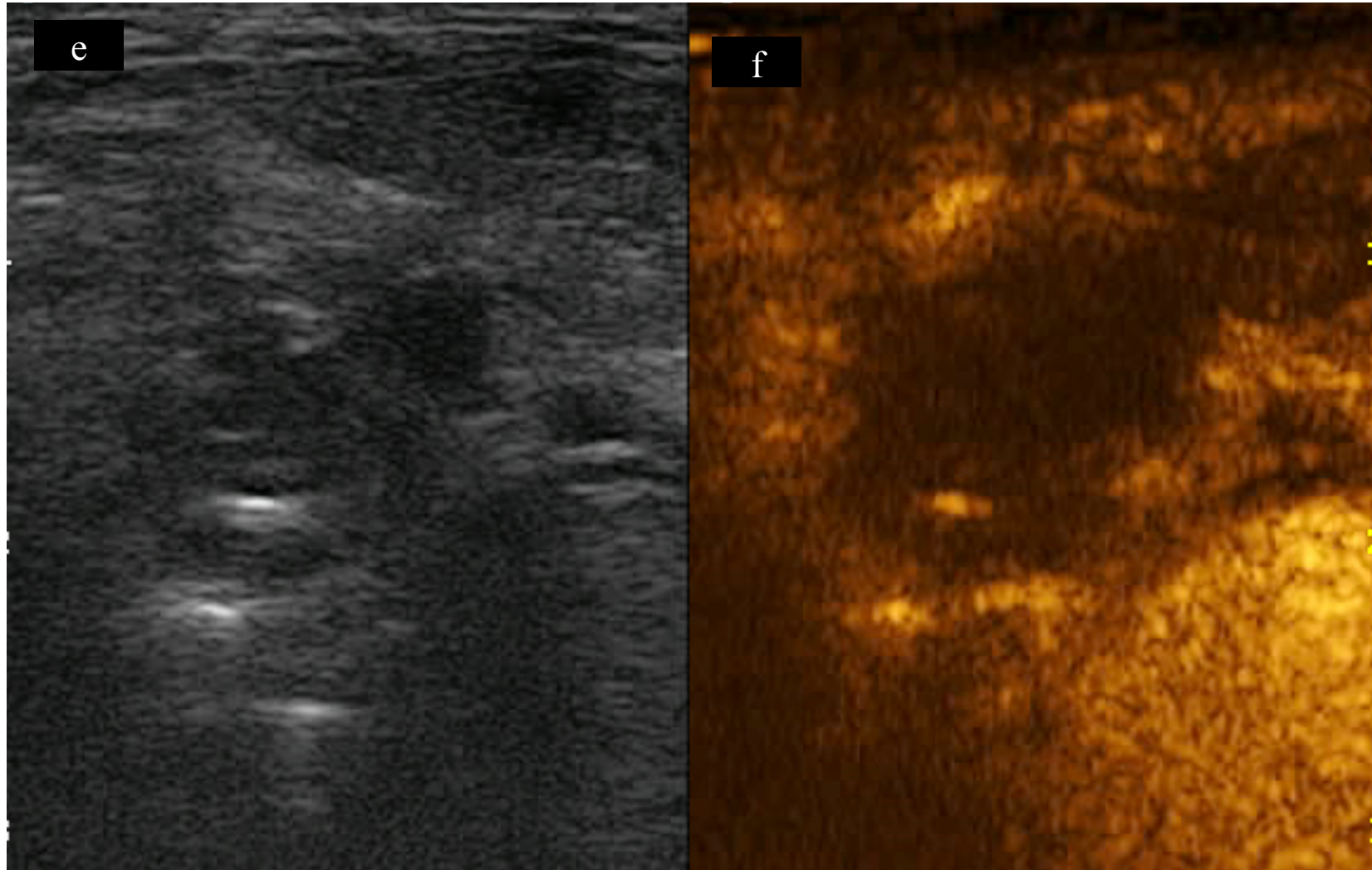
J Clin Endocrinol Metab. 2013 Jan;98(1):E92-7. doi: 10.1210/jc.2012-2991. Epub 2012 Nov 12.



## LA in metastatic lymph nodes from MPCT



# LA in metastatic lymph nodes from MPCT

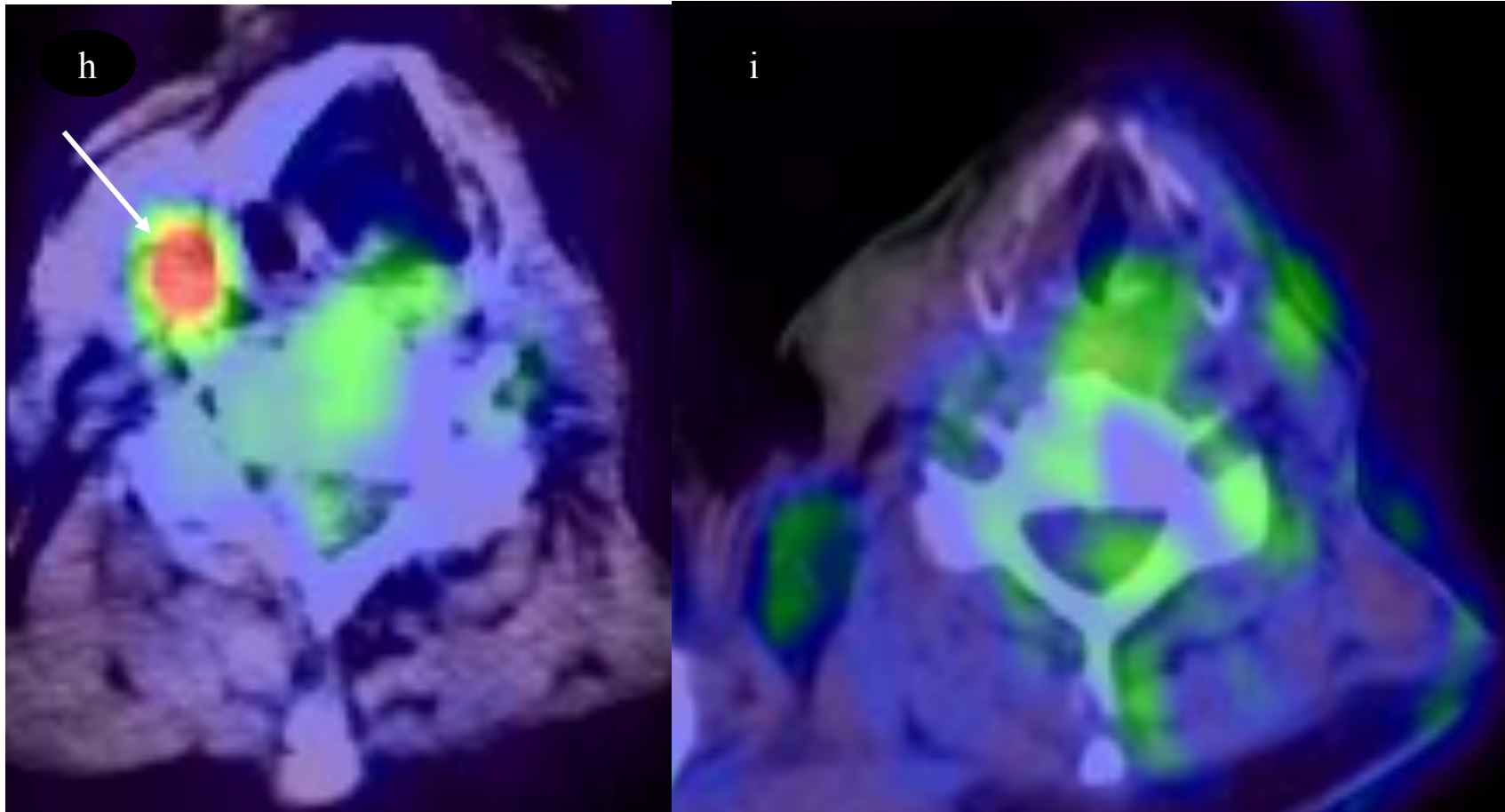




# LA in metastatic lymph nodes from MPCT

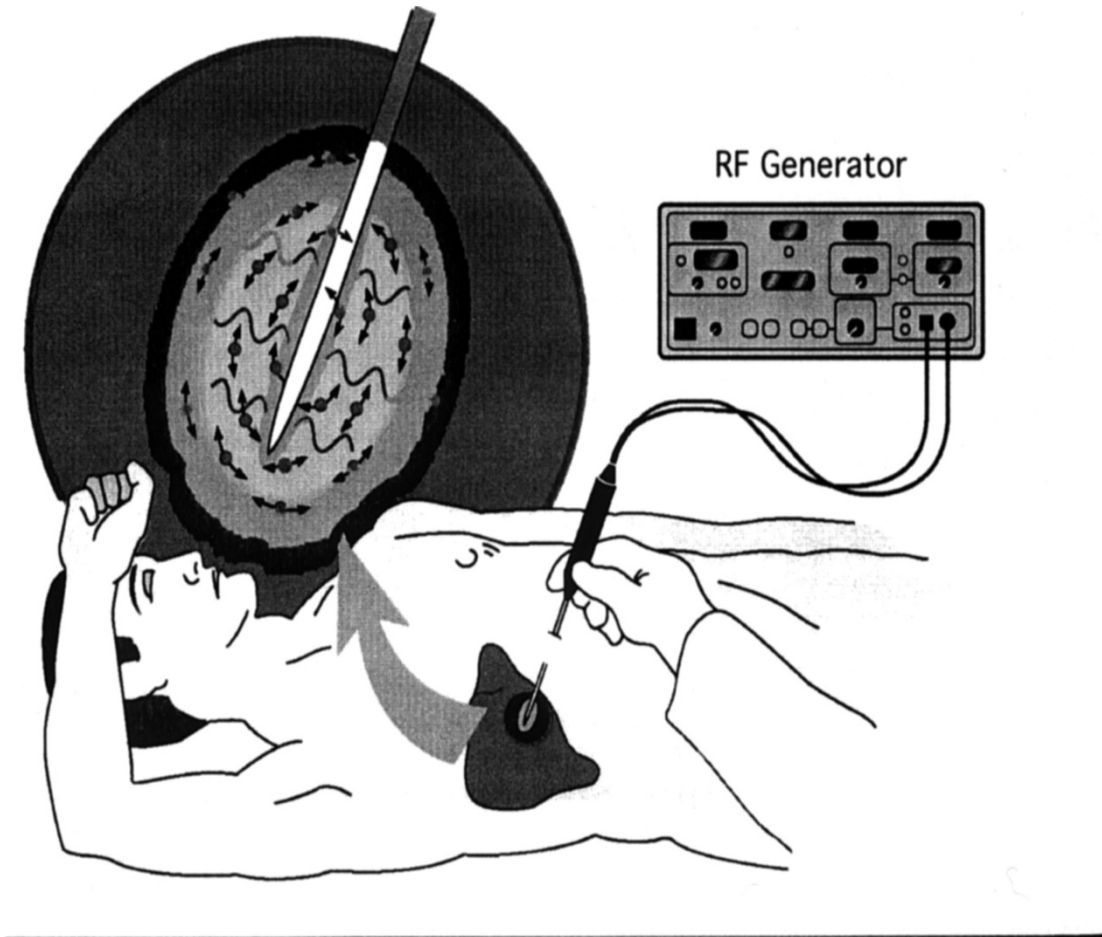
Treatment of Metastatic Lymph Nodes in the Neck from Papillary Thyroid Carcinoma with Percutaneous **L**aser Ablation.

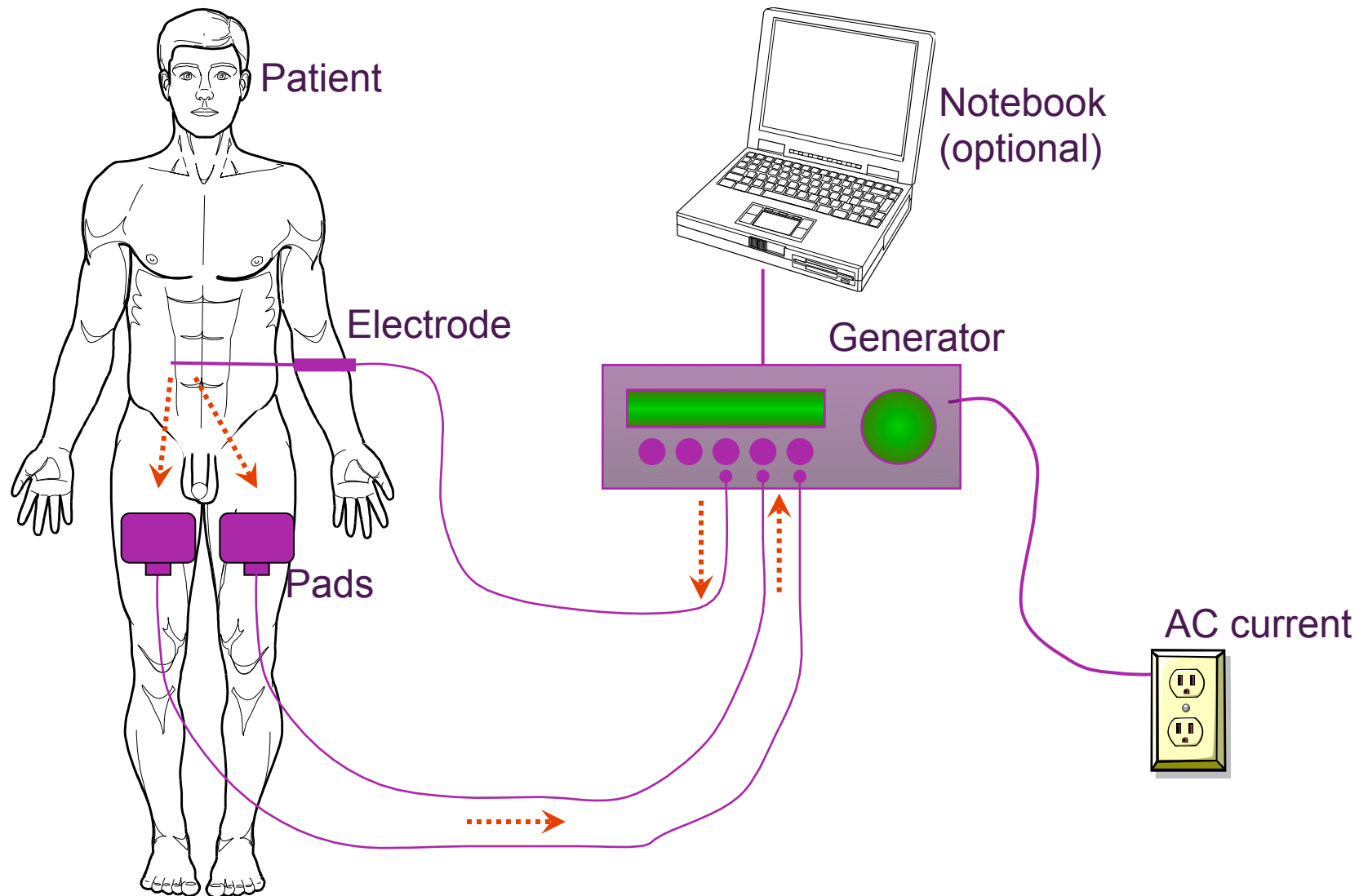
**Mauri G, Cova L, Ierace T, Baroli A, Di Mauro E, Pacella CM, Goldberg SN, Solbiati L.**  
Cardiovasc Intervent Radiol. 2016 Jul;39(7):1023-30. doi: 10.1007/s00270-016-1313-6. Epub 2016 Feb 24.

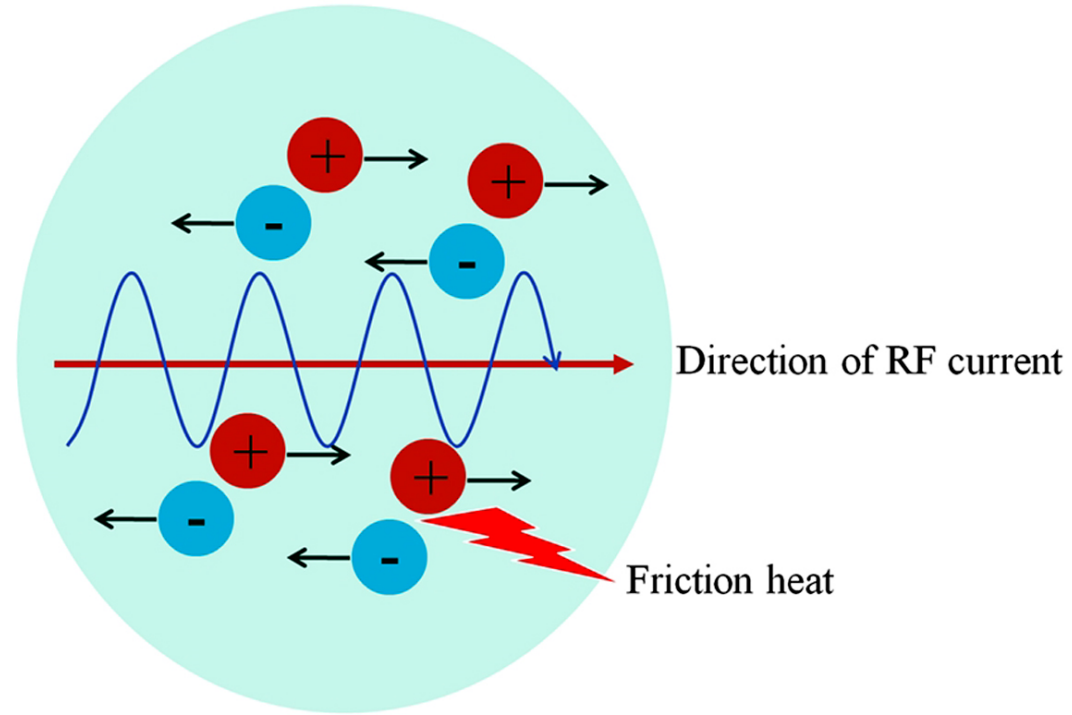




# radiofrequency ablation

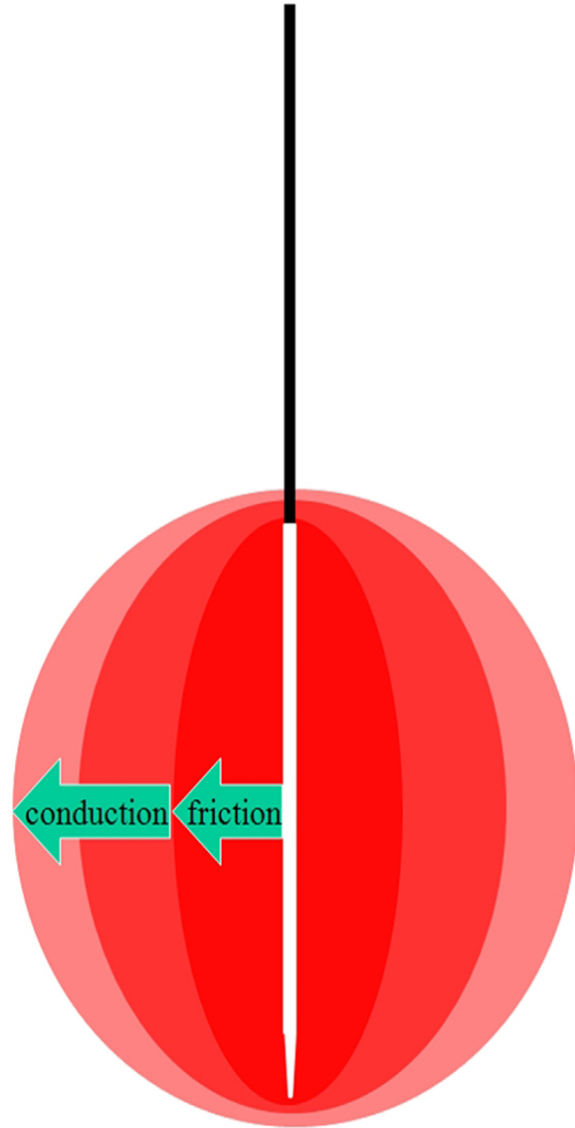






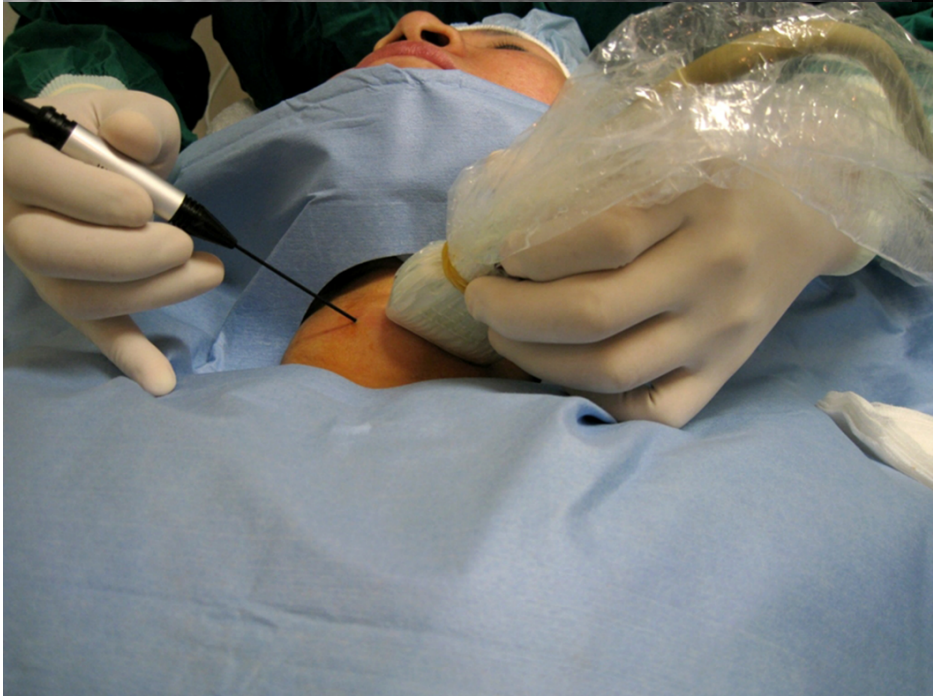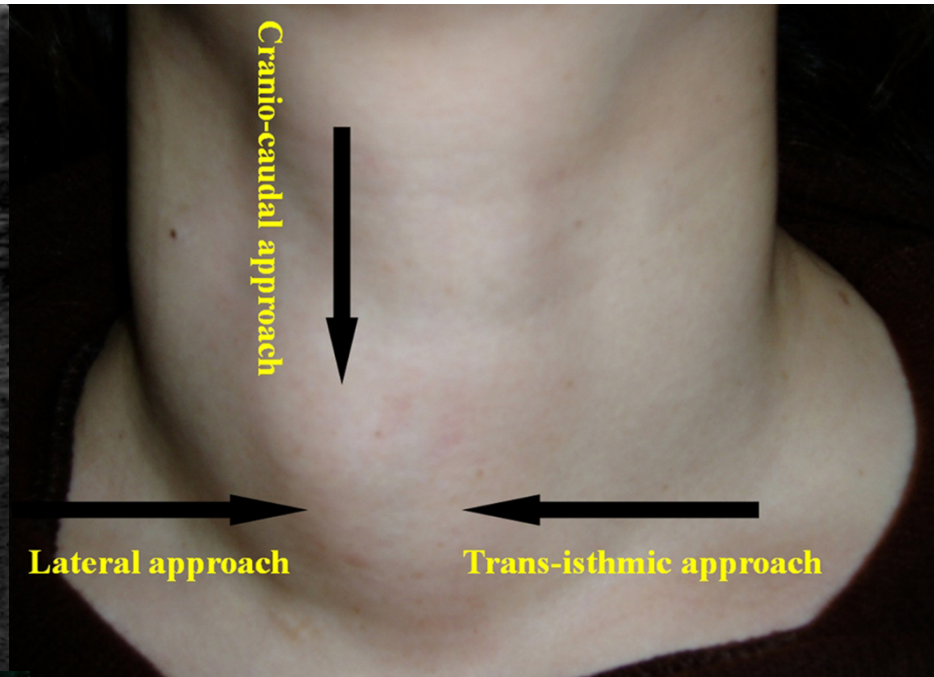
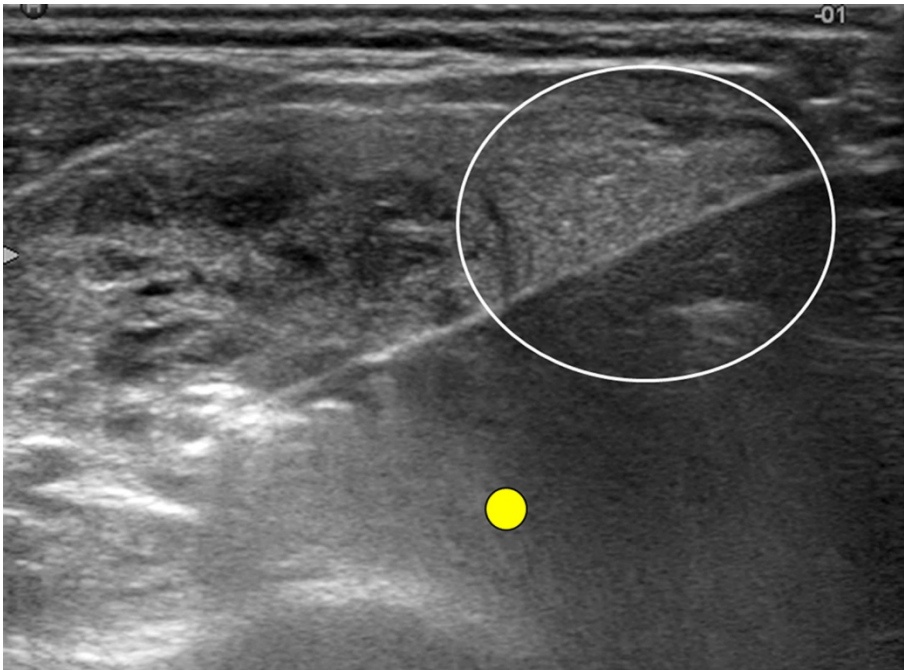
**Ionic agitation and formation of frictional heat.**

Tissue ions are agitated by application of alternating electric current. Ionic agitation results in ion friction, which in turn causes heat production.



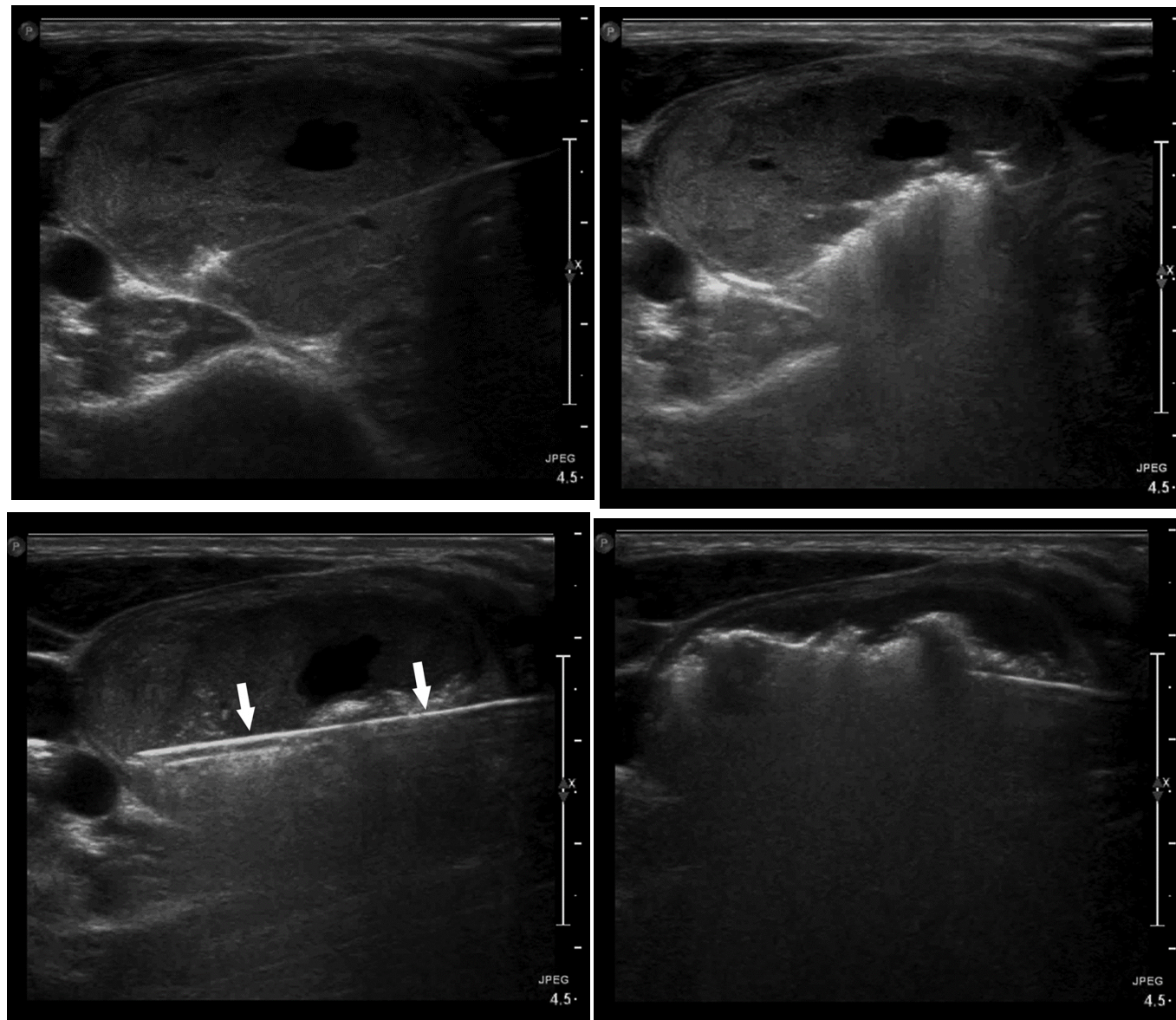
**Heat propagation through target tumor.**

Immediate tissue coagulation necrosis is achieved by frictional heat generated in vicinity of electrode, but electrode-remote tumor tissue is ablated more slowly, via conductive heat

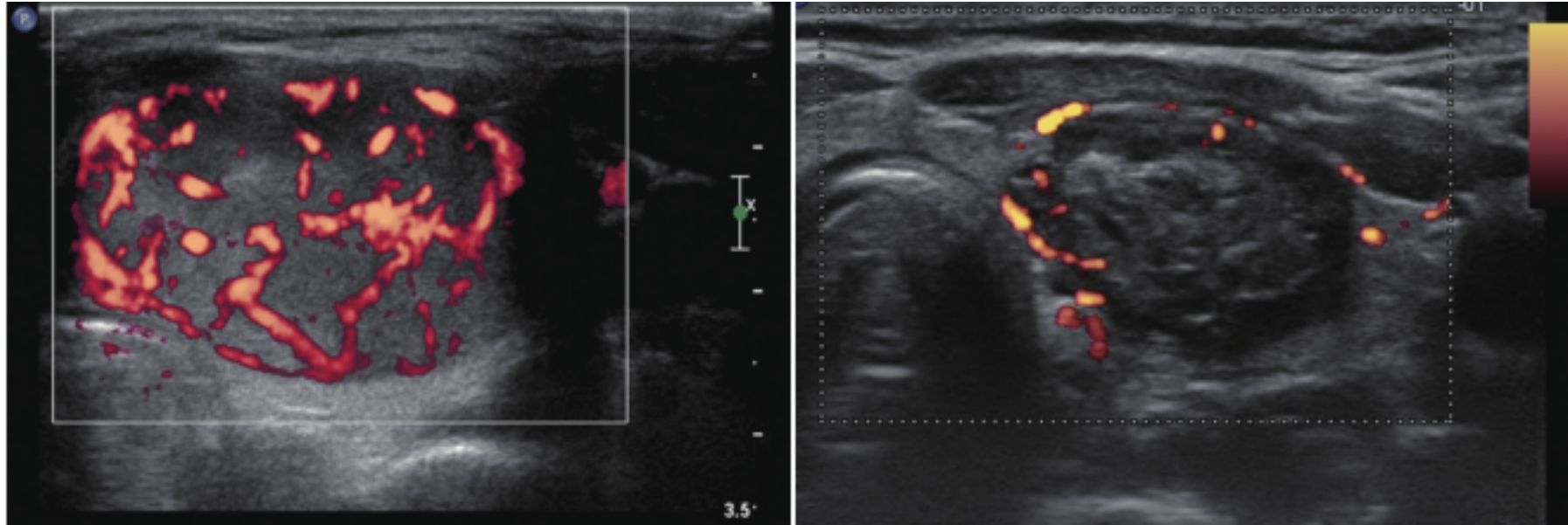


Positions of operator and patient. Patient is placed in supine position with mild neck extension, and operator stands close to patient's head. Left hand of operator holds US probe and right hand of electrode.

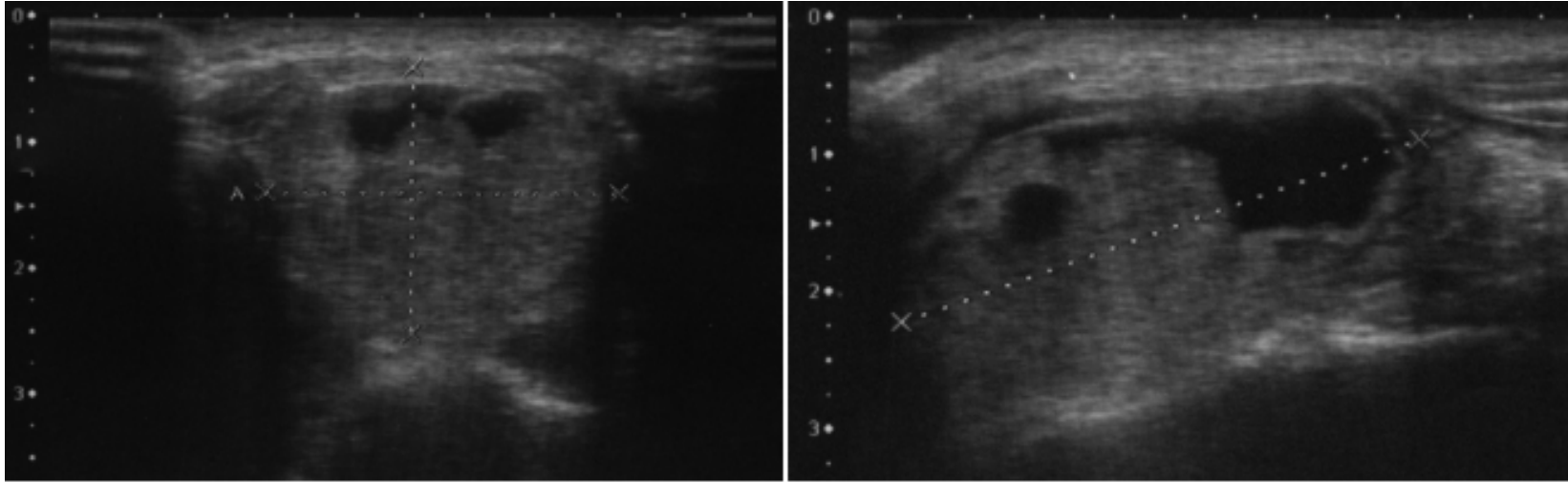




**Sequential US images of moving shot technique showing complete ablation of nodule margins.** A, B. Transverse US images showing initial placement of electrode at periphery of deep and remote portion of target nodule; ablation area was small at periphery and large in central safe area. C, D. Transverse US images showing re-location of electrode in untreated area. Electrode was continuously moved backward and in superficial direction within thyroid nodule. Entire length of electrode was always well demarcated (arrows).

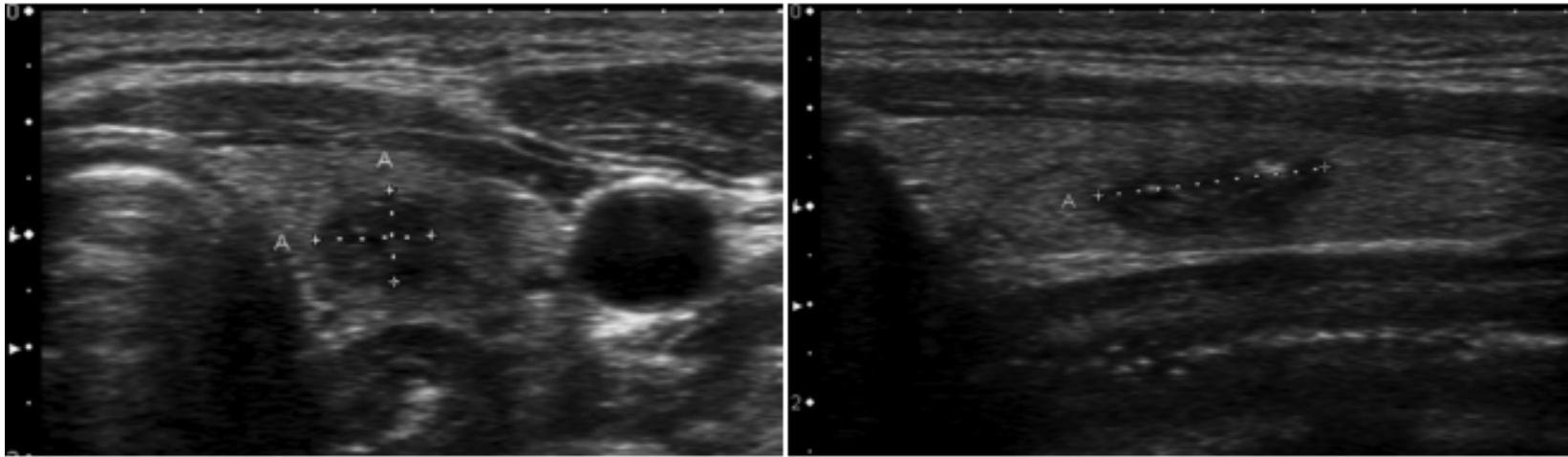


Transverse US images of well-ablated thyroid nodule, before (A) and 12 months after (B) radiofrequency ablation, showing size reduction, decreased echogenicity, and lack of internal vascularity.



A

B



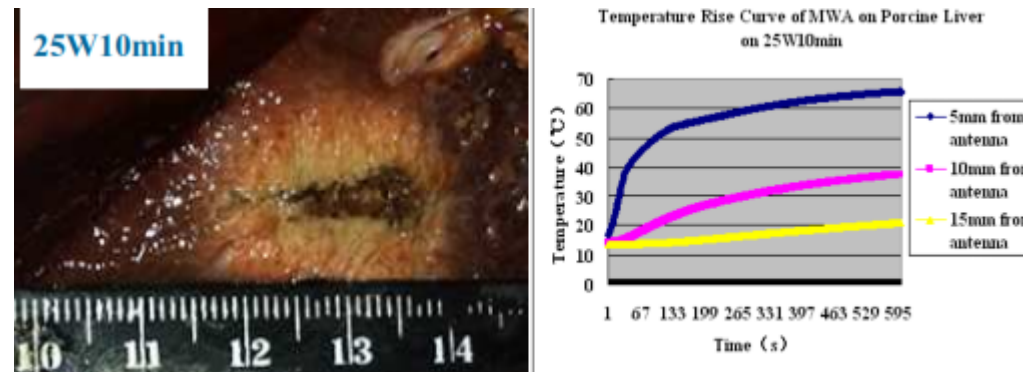
**Transverse and longitudinal US images showing marked shrinkage of ablated nodule.** Images obtained before (A, B) and 54 months after (C, D) radiofrequency ablation, showing that ablated thyroid nodule had decreased markedly in size; only small scar-like lesion remained.

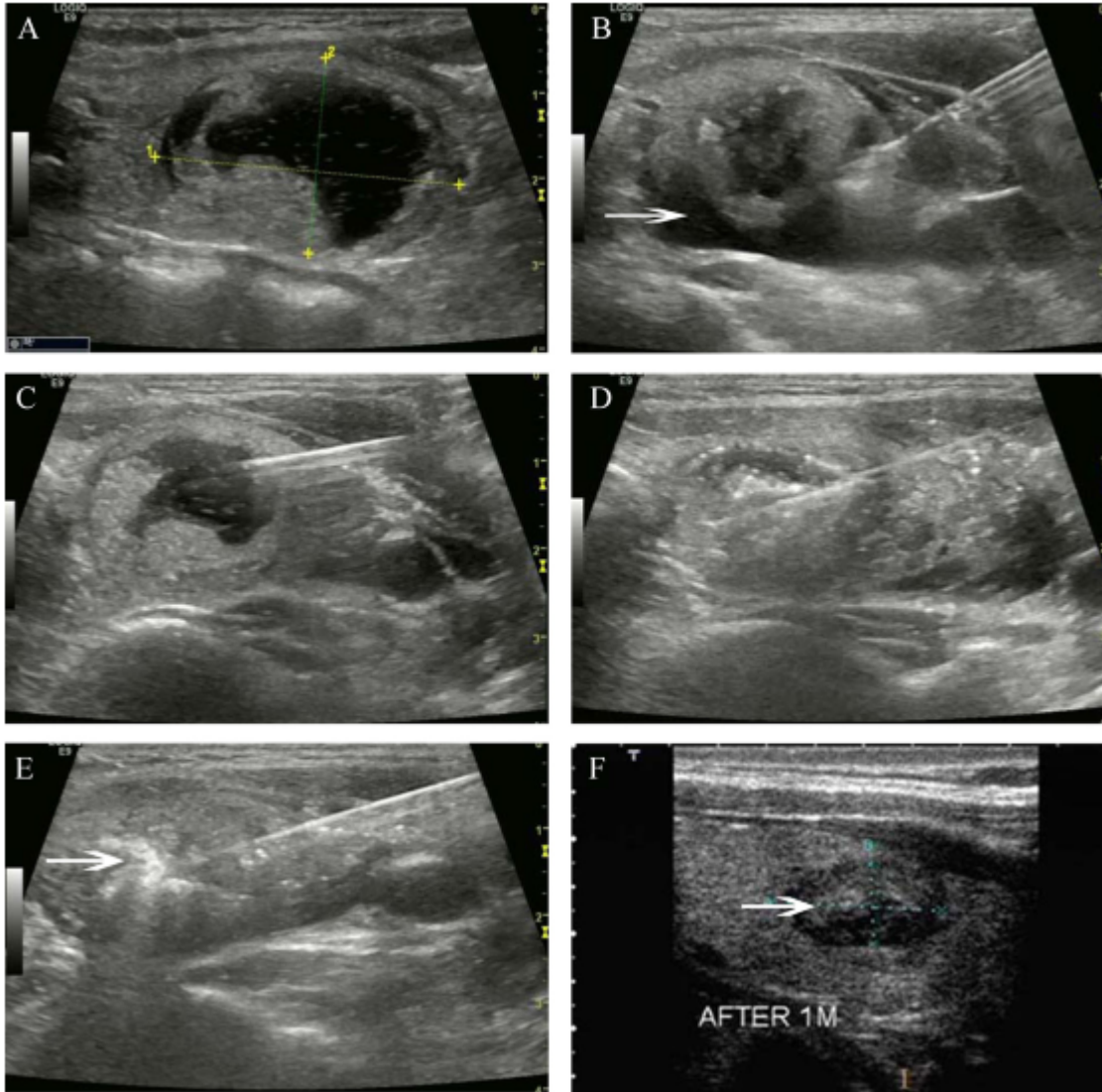


# MWA



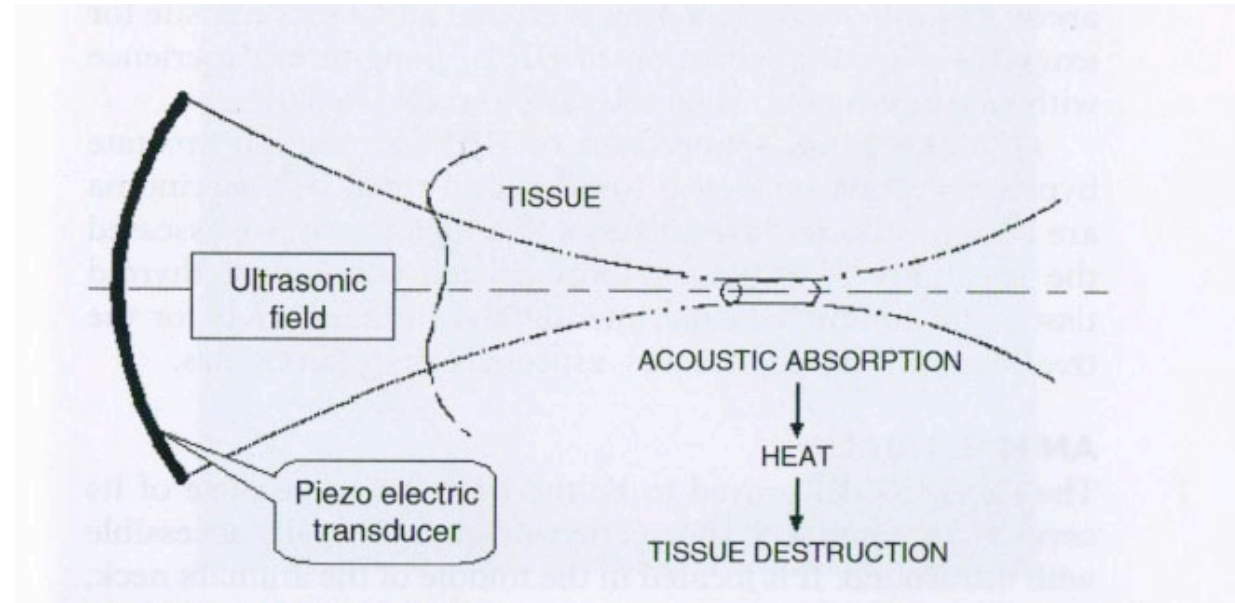
Top: the antenna in this study, 16-gauge, a 10 cm shaft, 3 mm between the narrow radiating segment and the tip of antenna (arrow). It is designed specially to treat superficial neck organ diseases. Bottom: 15-gauge, an 18 cm shaft, 11 mm between the narrow radiating segment and the tip of antenna (arrow). It is used for abdominal tumors.






A 40-year-old woman had a mainly cystic nodule in the left lobe of her thyroid gland. And then here is the key procedure of the treatment. (A) Ultrasound examination revealed the nodule to be 9.72 ml in volume before microwave ablation. (B) Under local anesthesia, a mixture of 0.9% lidocaine and physiological saline was infused into the surrounding thyroid capsule to achieve a “liquid isolating region” (arrow), protecting the vital structures of the neck (carotid artery, trachea, esophagus, nerve) from the Thermal injury. (C) For mixed/mainly cystic nodules, we performed microwave ablations only after aspiration of internal fluid. To extract the internal fluid of the nodule, a 20 ml syringe was usually used. (D) After aspiration of internal fluid, the size of the nodule reduced significantly. (E) During the microwave cooled microwave antenna (16G) was positioned in the thyroid nodule. Sonogram obtained during treatment shows typical hyperechoic region (arrow) surrounding antenna. (F) At follow-up ultra sonograph examination 1-month after treatment, the volume of nodule was reduced to 0.58 ml, 6% of original (arrow).

# High-Intensity Focused Ultrasound HIFU

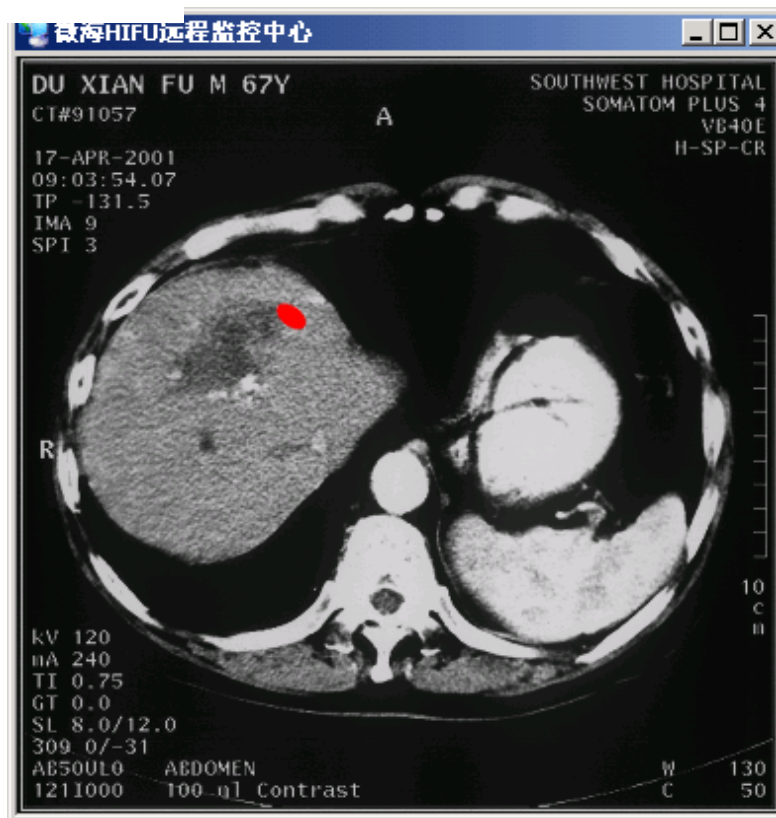
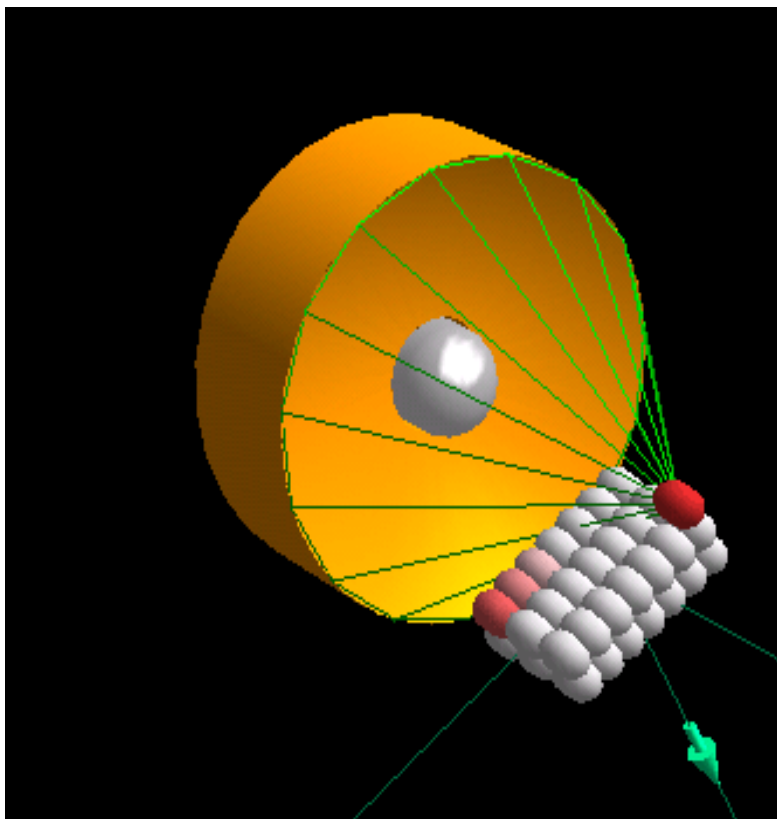


1. HIFU is a noninvasive ablative method based on the generation of extracorporeal ultrasound waves focused on target tissue. The energy propagates through the skin without damaging it up to the focal point where the temperature increases.
2. Acoustic field focusing limits the heated volume to only a few cubic millimeters, causing coagulative necrosis without affecting adjacent tissues

# HIFU

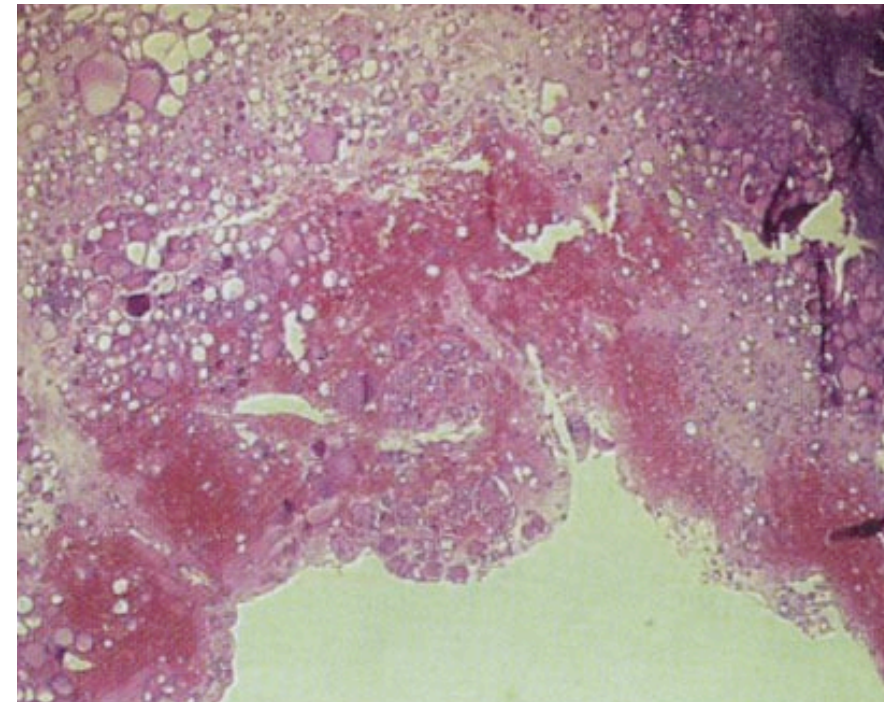
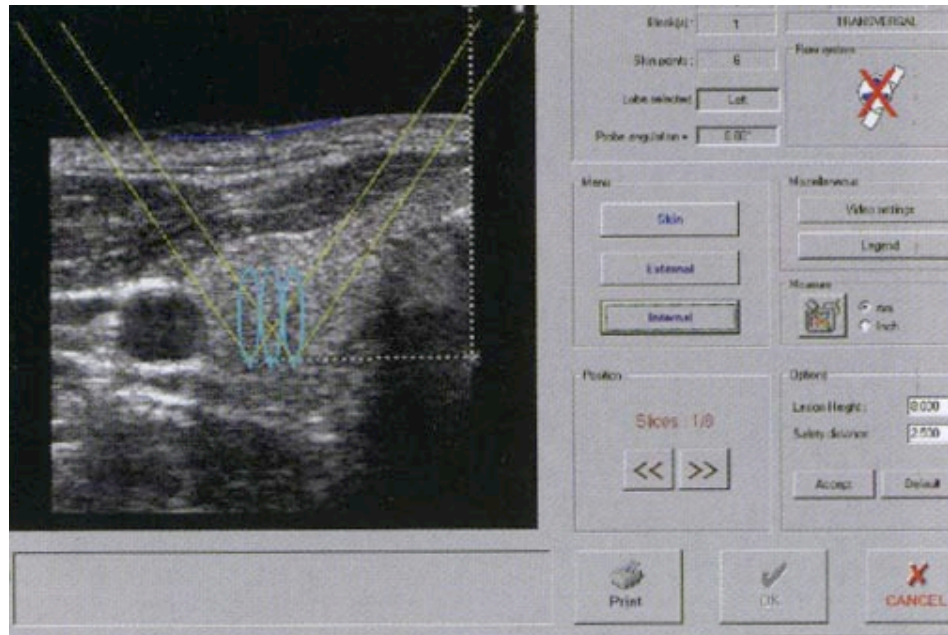


2001050707



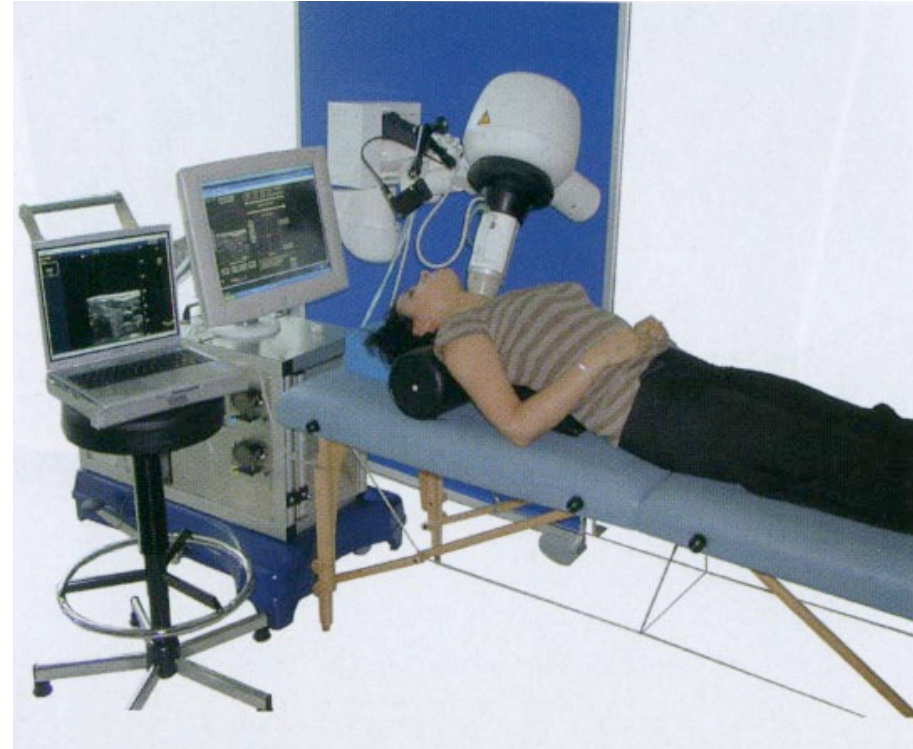


# High-Intensity Focused Ultrasound HIFU



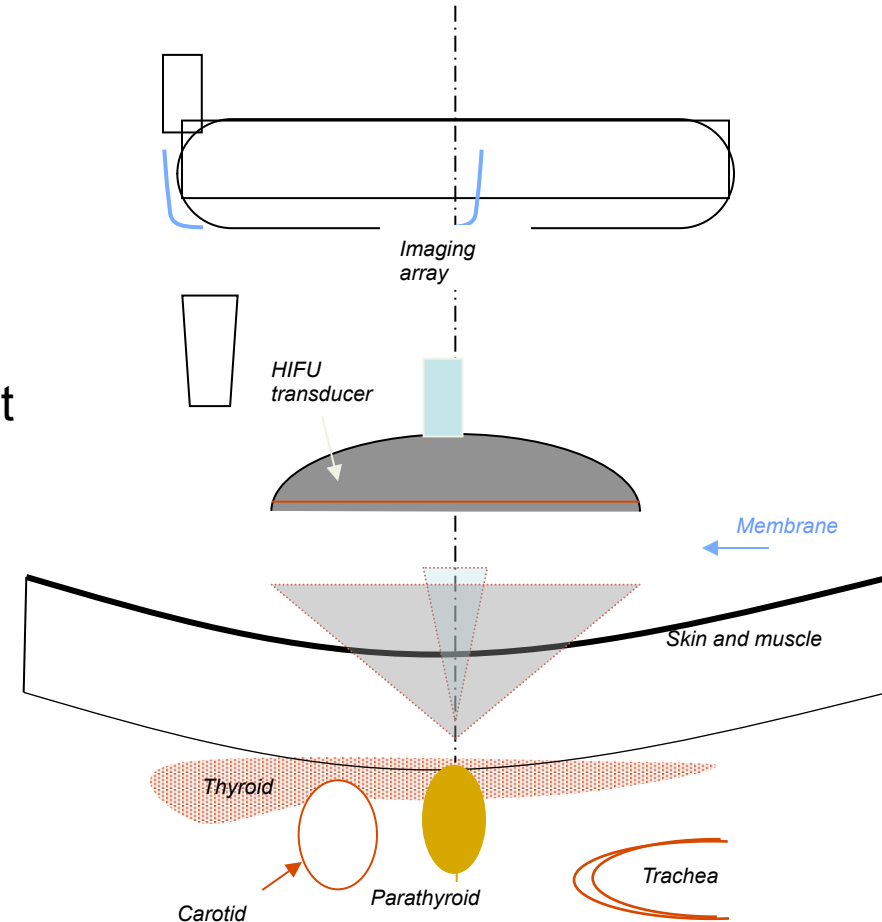
# High-Intensity Focused Ultrasound

The process is US-g. Electronic cabinet include an extracorporeal head, a cooling unit, and an ultrasound scanner. The treatment head comprises an integrated 12-MHz linear array transducer for imaging the target and one transducer operating at 3 MHz for delivering ultrasound energy to the target. The energy level was adapted to the patients to obtain coagulative temperatures in the target, with a cautious maximum of 200-300 J per pulse.



# Ultrasound-guided HIFU

- One single visualization and treatment unit (VTU) for ultrasound guided imaging and HIFU treatment
- Coupling and cooling kit (membrane)
- Real-time imaging and treatment
- High-precision: **1 mm**
- Target small regions of interest: **2x2x8 mm<sup>3</sup>**
- Reaches coagulation temperature of tissue: **85°C**



**Integrated diagnostic and treatment in one single head**  
**Accurate treatment with millimetric precision**

# Ultrasound-guided HIFU

## **Main advantages**

- HIFU holds potential for treatment of small benign nodules in the neck
  - Noninvasive therapy
1. Live view of ultrasound imaging
  2. Live view of HIFU beam
  3. Full control over targeted areas
  4. Full control of dose delivery

## **Main disadvantages**

- Cost
- Availability
- Sedation/narcosis
- Learning curve, complex set-up
- Long-term efficacy